



**PRESENTING CLINICAL SIGNS**

**DATE** History: Murmur. Cardiomegaly on X-ray. History of hyperthyroidism – has not been receiving thyroid medications since June. T4 yesterday was 17. BP 200 mmHg.

11/2/21

**ECHOCARDIOGRAPHIC FINDINGS**

2D, M-mode, Doppler study.

**PERFORMED BY:**

Dr. Meredith Swart

**INTERPRETED BY**

Keith Blass, DVM,  
MS, DACVIM  
(Cardiology)

There is moderate left atrial dilation. The mitral valve appears normal, though mild mitral regurgitation is present. There is mild symmetrical left ventricular hypertrophy. Left ventricular internal dimensions are normal. Left ventricular systolic function is hyperdynamic. The aorta and aortic valve are normal. Right atrial and right ventricular dimensions are normal. The tricuspid valve is normal. The pulmonary artery and pulmonic valve are normal. No pericardial effusion or cardiac masses are seen.

**PATIENT**

Sophie Brulte

LA – 18.6 mm  
LA/Ao – 2.05  
IVSd – 6.0 mm  
LVPWd – 6.0 mm  
LVIDd – 16.5 mm  
LVIDs – 6.4 mm  
FS – 61%  
LVOT – 1.68 m/s  
RVOT – 0.92 m/s

**SPECIES**

Feline

**ASSESSMENT/RECOMMENDATIONS**

**BREED**

DSH

This examination demonstrates mild hypertrophy of Sophie's left ventricular walls, with differentials for this finding including hypertrophic cardiomyopathy, cardiac thyrotoxicosis, hypertensive cardiomyopathy, or a combination of one or more. Secondary to her hypertrophy, Sophie has moderate dilation of her left atrium. Given this, Sophie is at risk for the development of congestive heart failure and/or thromboembolic disease, therefore, careful monitoring for signs associated with these conditions is recommended.

**SEX**

FS

Recommended therapy based on this exam includes benazepril (1.25 mg SID) and clopidogrel (18.75 mg SID). Therapy with amlodipine (0.625-1.25 mg SID) is recommended if Sophie's hypertension persists once her hyperthyroidism is controlled.

**AGE**

11 y

A renal/electrolyte profile is recommended in 1-2 weeks. A recheck echocardiogram is recommended in 6 months. Thoracic radiographs are recommended if Sophie experiences respiratory clinical signs.

**WEIGHT**

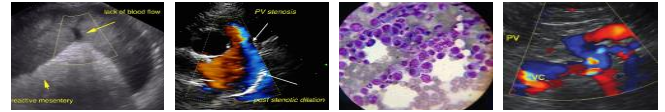
11.8 lb

**HOSPITAL NAME**

Swart Veterinary  
Imaging

**REFERRING VET**

Dr. Swart



DATE

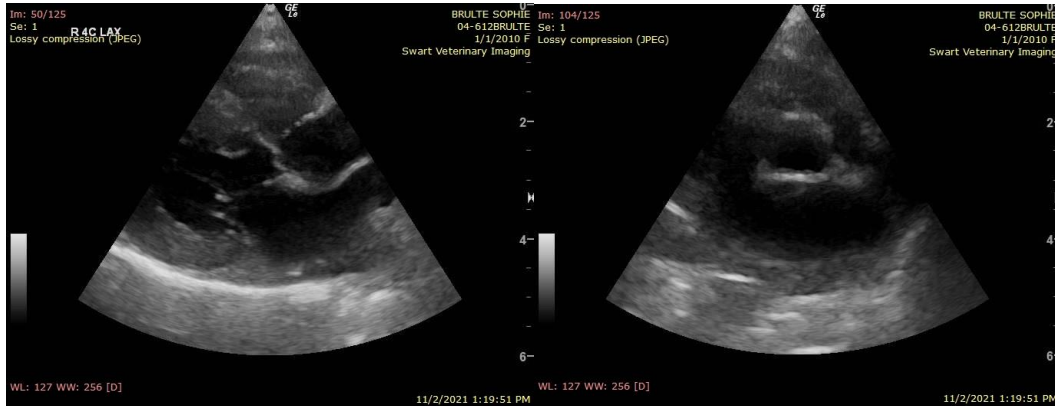
11/2/21

PERFORMED BY:

Dr. Meredith Swart

INTERPRETED BY

Keith Blass, DVM,  
 MS, DACVIM  
 (Cardiology)



PATIENT

Sophie Brulte

The information and recommendations provided are based on the images presented by the referring veterinarian. No evaluation can be communicated regarding pathology that was not visible in the image/video clips provided.

SPECIES

Feline

Thank you for this referral. If the clinical or image interpretation does not parallel your findings or if I can be of any further assistance please contact me.

BREED

Keith Blass, DVM, MS, DACVIM (Cardiology)  
 KeithBlass@gmail.com  
 631-804-5754

DSH

SEX

FS

AGE

11 y

WEIGHT

11.8 lb

HOSPITAL NAME

Swart Veterinary  
 Imaging

REFERRING VET

Dr. Swart